

# Euthanasia for Broiler Chickens: Manual and Mechanical Cervical Dislocation Methods

*Authored by Leonie Jacobs, Assistant Professor, Animal and Poultry Sciences, Virginia Tech; Dianna V. Bourassa, Assistant Professor, Poultry Science, Auburn University; Caitlin E. Harris, Graduate Student, Poultry Science, The University of Georgia; R. Jeff Buhr, Research Physiologist, U.S. Department of Agriculture–Agricultural Research Service, U.S. National Poultry Research Center*

## Introduction

When a broiler chicken is injured, stunted in growth, immobile, or otherwise unable to eat or drink, it is in the animal's best interest to take it out of the flock for euthanasia rather than to leave the bird to eventually die. Euthanasia, or "good death," is not a pleasant job, but it is important that it is effective, relatively quick, and easy to administer. For the bird, it should be done with minimal unavoidable pain or distress.

Manual cervical dislocation (CD) is the most common method for euthanizing broiler chickens, but uniform application for numerous birds can be challenging. Therefore, using a tool (the mechanical method) such as the Koechner Euthanizing Device could be an alternative when multiple birds are to be euthanized, such as during flock depopulation. For this study, we evaluated the Koechner Euthanizing Device and

manual cervical dislocation of 200 broiler chickens ranging from 36 to 43 days of age at scheduled flock terminations.

## Manual Cervical Dislocation

Manual cervical dislocation (CD) is probably the most common euthanasia method used for broiler chickens. For cervical dislocation, the bird's head is grasped behind the skull at the mandibles between the thumb and the index finger, followed by a quick, firm pull down and twist dorsally to stretch the neck and separate the skull from the spinal column (figure 1A).

In this study, the operator performed CD either while holding the bird (figure 1B) or after the bird was placed into a killing cone (figure 1C).

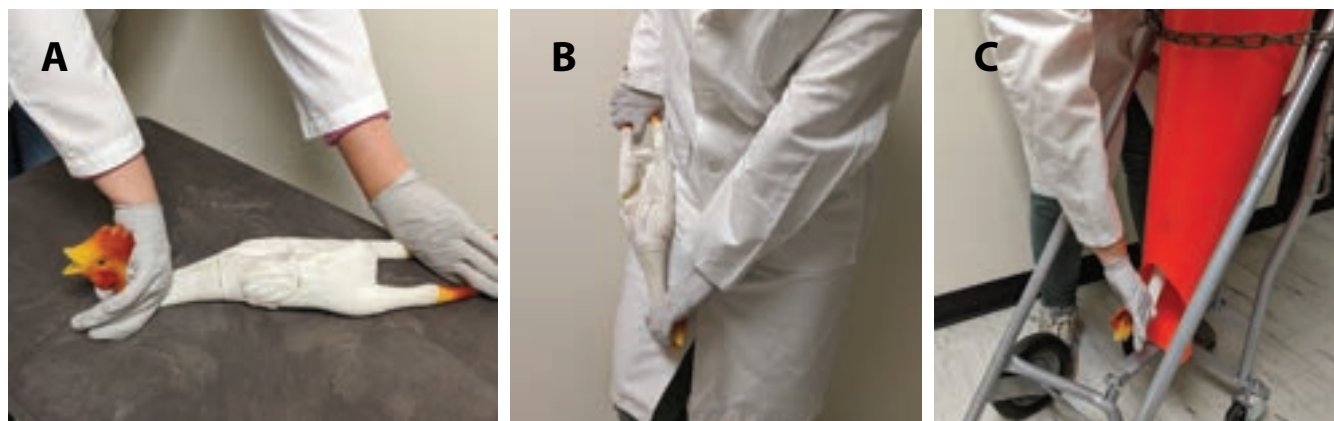


Figure 1: Application of manual cervical dislocation (A), either performed while holding the bird by the legs, supporting its body on the operator's hip (B), or by placing the bird in a killing cone, followed by a firm pull down to dislocate the spine from the skull (C). (Photos courtesy of Caitlin Harris and Nicole Bartenfeld Josselson, U. S. Department of Agriculture–Agricultural Research Service, Athens, Georgia.)

## Koechner Euthanizing Device

We applied the Koechner Euthanizing Device (KED-C, Clear View Enterprises LLC, USA) in two different scenarios, which we called KED and KED+. Figure 2A illustrates the manufacturer recommendation, placing the “plier” blades perpendicular to the neck and parallel to the ground at the base of the skull. The jaws were closed slowly until the blades were in light contact with the neck skin and then the handles were quickly brought together for 1 second and then removed. The KED is available in four sizes corresponding to the size of the birds to be euthanized, from day of hatch chicks to breeders.

We placed each broiler in a killing cone (figure 2B) to facilitate observing the animals’ responses while restricting clonic and tonic convulsions, and then observed and recorded the time it took for the birds to die. Figure 2C illustrates the second method: a two-step application (KED+) of the KED, in which after the above-mentioned application, the head was twisted an additional 90 degrees, similar to what occurs during manual cervical dislocation to achieve additional separation of the skull from the spinal column. Depending on the sample day (three days in total), we placed birds in the cone before or after applying the euthanasia method. On day 1, birds were euthanized prior to placement in the cone; on days 2 and 3, birds were euthanized after placement in the cone.




Figure 2: Application of the Koechner Euthanizing Device (A) following manufacturer recommendations, (B) in a killing cone to record bird responses, and (C) with a two-step approach (KED+), applying an additional twist of the head at a 90 degree angle, similar to manual cervical dislocation. (Photos courtesy of Caitlin Harris and Nicole Bartenfeld Josselson, USDA-ARS Athens, Georgia.)

## Observing and Recording Onset of Death

We assessed death as the culmination of the loss of brain stem reflexes (which indicate deep unconsciousness and/or brain stem death) and the subsequent cessation of physical movements (spinal cord death). The brain stem connects the brain to the spinal cord and facilitates the regulation of most autonomous body functions (respiration, induced eye movements, balance/posture, and blood pressure). Reflexes and physical movements were observed to determine how long it took to attain death. We focused on the induced nictitating membrane reflex of the eye (figure 3), gasping (opening and closing of beak), and visible physical muscle movements, including the vent (cloaca), which were visible with birds placed in

the cone. The time of cessation of physical movement was interpreted as the onset of death, as the most conservative measure. We also recorded the presence of external blood loss and the spinal column damage “gap” (figure 4) to the neck from euthanasia.

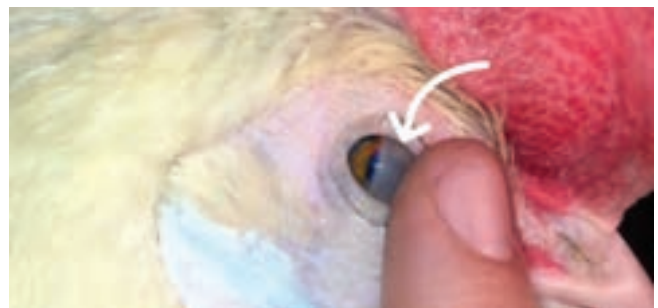

Figure 3: A chicken's third eyelid, or nictitating membrane. Touching the corner of the eye will induce the reflex if the animal is still alive. (Photo Leonie Jacobs, Virginia Tech)

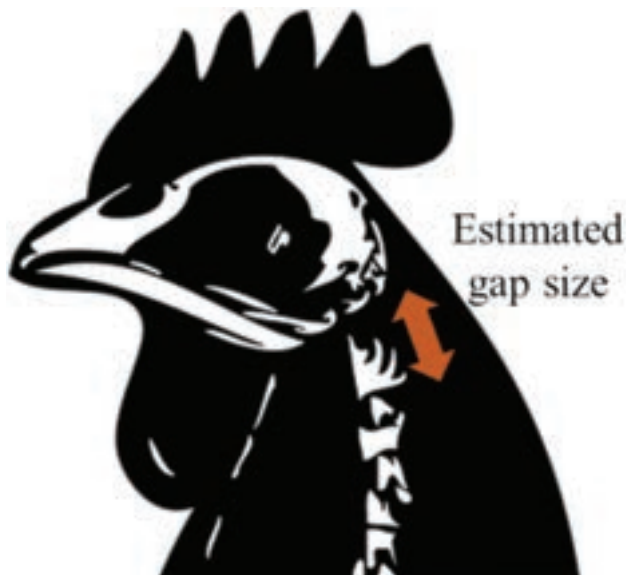

Figure 4: We recorded the damage to the spinal column by measuring the gap between the Atlas vertebra and the skull post-mortem, in 1 centimeter increments. (Image used and modified with permission from <http://www.freestockphotos.biz>.)

## Findings and Conclusions

For manual cervical dislocation (CD), KED, and KED+, all broilers immediately displayed clonic/tonic convulsions upon euthanasia, indicating a rapid progression to a state of unconsciousness (therefore insensible to pain stimuli) and the loss of brain control functions. Results, shown in figure 5, indicate that it took 18 seconds longer for birds to die (absence of skeletal-muscle movements) when they were euthanized with KED (106 seconds for KED and 109 seconds for KED+) compared with CD (89 seconds), based on durations of induced reflexes and movements. The nictitating membrane-induced reflex and gasping remained for about 40 seconds longer in KED and KED+ birds (62 and 60 seconds, respectively) compared with CD birds (18 seconds). Furthermore, in approximately half the KED birds, the nictitating membrane reflex and gasping initially were absent but returned; in comparison, after CD, only 12% of birds regained these reflexes. The majority of birds euthanized with the KED (84%) had external blood loss, compared with no external blood loss after CD. Additionally, the damage to the spine resulted in a gap between skull and Atlas vertebra of 1.1 centimeters after KED and 1.7 centimeters after KED+ compared with CD carcasses with a gap of 1.8

centimeters. Although the gap for KED+ increased compared with KED and was similar to CD, the time to death based on muscle-skeletal movements remained longer for KED+ compared with CD. Greater spine separation during euthanasia does not appear to explain the shorter time to death of CD compared with KED or KED+.

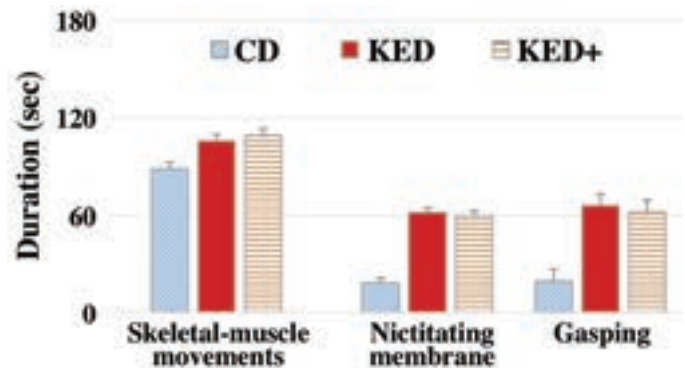


Figure 5: Durations for musculoskeletal-muscle movements in seconds (mean values  $\pm$  standard error), the nictitating membrane reflex, and the gasping reflex, after application of each euthanasia method: manual cervical dislocation (CD); Koechner Euthanizing Device (KED); and Koechner device with additional head extension (KED+).

For the indicators we observed in broilers, manual cervical dislocation had shorter time to death compared with the KED applications. Extending the spinal column gap with the two-step KED+ application was achieved but did not shorten the time to death. When numerous broilers are to be euthanized, as for flock depopulation or necropsy, the use of the KED for euthanasia is a practical, safe, and efficacious method. For euthanasia of a single broiler or a few birds in a flock, cervical dislocation is the obvious method and can be performed by a single person without any equipment. However, CD can be physically straining on the operators, and requires training and practice to maintain proficiency to be applied appropriately to numerous broilers. Thus, the need remains to find methods equal to or better than cervical dislocation.

## Acknowledgements

This study was approved by the Institutional Animal Care and Use Committee (IACUC) of Virginia Tech (18-124) and was partly funded by the U.S. Poultry Foundation (#BRF011).

Full scientific findings are published at <http://doi.org/10.3390/ani9020047> and can be cited: Jacobs L., D. V. Bourassa, C. E. Harris, and R. J. Buhr. 2019. "Euthanasia: Manual Versus Mechanical Cervical Dislocation for Broilers." *Animals* 9 no. 2: 47.

This work was supported by the USDA National Institute of Food and Agriculture, Hatch project VA-160103.